

**SERUM ZINC, COPPER AND ALPHA TOCOPHEROL CONCENTRATIONS
IN DOGS WITH ECZEMA***

Alev AKDOĞAN KAYMAZ, Tuncay ALTUĞ***, Utku BAKIREL**,
Remzi GÖNÜL**, Ömer GÜZEL****, Hüseyin TAN****

- * The work was supported by The Research Fund of The University of Istanbul.
Project No: 29/96.
- ** İstanbul University, Faculty of Veterinary Medicine, Dept. Of Internal Medicine,
Avcılar, İstanbul-TURKEY.
- *** İstanbul University, Faculty of Veterinary Medicine, Dept. Of Medical Biology,
Avcılar, İstanbul-TURKEY.
- **** Biruni Laboratuvarı Şişli, İstanbul-TURKEY

EGZEMALİ KÖPEKLERDE SERUM ÇİNKO, BAKIR VE ALFA-TOKOFEROL DÜZEYLERİ *

Özet: İstanbul'da, ekzema vakalarının çoğu, sadece ekmek ya da et ile beslenen köpeklerde görülmektedir. Bu çalışmaya sadece dengelenmemiş ev yemeği ile beslenen egzemalı köpekler dahil edildi. Egzemalı grup Sivas Kangal, Alman Kurt ve kırma köpeklerden, kontrol grubu ise sağlıklı köpeklerden oluşturuldu (Sivas Kangal). Deri örnekleri mikroskopik olarak muayene edildi. Bütün köpeklerde serum çinko (Zn), bakır (Cu) konsantrasyonu ve alfa-tokoferol (α -TCP) düzeyleri ölçüldü. Kontrol grubu ile karşılaştırıldığında egzemalı köpeklerde serum bakır düzeyinin bariz bir şekilde azaldığı ve serum çinko düzeylerinin ise arttığı saptandı ($p<0.05$). Fakat, egzemalı köpeklerin alfa tokoferol düzeylerinde belirgin bir değişiklik izlenmedi. Serum bakır düzeyi ve α -TCP konsantrasyonu arasında negatif bir korelasyon saptandı. Verilerimiz sonucu yetersiz beslenme ile azalmış bakır ve artmış çinko konsantrasyonlarının düzeylerinin köpeklerde egzemanın gelişiminden sorumlu olabileceği kanısına varıldı.

Anahtar sözcükler : Egzema, köpek, çinko, bakır, alfa-tokoferol.

SERUM ZINC, COPPER AND ALPHA TOCOPHEROL CONCENTRATIONS IN DOGS WITH ECZEMA*

Abstract: In Istanbul, most cases of eczema have been seen in dogs which have been fed with only meat or bread. Only the dogs with eczema, that were fed with unbalanced home diets were included in this study. The eczema group contained the dogs of Karabash, German Shepherd and mixed breeds and control group contained healthy dogs (Karabash). Skin samples were examined microscopically. Serum zinc (Zn), copper (Cu) concentrations and alpha tocopherol (α -TCP) levels were measured in all dogs. Serum copper concentrations were significantly decreased and serum zinc concentrations were increased in dogs with eczema compared to the control group ($p < 0.05$). But there was no significant change in serum α -TCP levels in dogs with eczema. There was a negative correlation between serum Cu and α -TCP concentrations. Our data concluded that restricted diet and decreased Cu and increased Zn concentrations might be responsible for the progress of eczema in dogs.

Key Words: Eczema, dog, zinc, copper, alpha-tocopherol.

Introduction

Low zinc (Zn) concentrations have been documented in dogs with spontaneous Zn-responsive dermatitis (1,8). Most cases of Zn-responsive skin diseases in dogs result from feeding soy, and/or cereal-based diets. Such diets are not deficient in Zn, but contain other substances that reduce the absorption of zinc (5,8).

Zinc has been used as adjunctive therapy for burns, wounds, recurrent Pyoderma and Seborrhoea, although no beneficial effects have been shown in dogs by controlled studies (3). Zinc has recently been added in increased amounts to at least one proprietary dietary supplement (5). Although there are good reasons for adding zinc to some canine diets, indiscriminate over supply of this trace element carries with it the risk of interaction with others and subsequent disturbances of mineral balance (3,5).

The clinical signs of experimentally induced zinc deficiency and naturally occurring zinc responsive deficiency dermatitis have been described in dogs (4,10). However, the diagnostic value of laboratory findings in zinc-deficient dogs has not been well documented (10).

There is considerable evidence that, in addition to its role as a component of many enzymes, zinc can function as a stabiliser of biomembranes (6). Red blood cells of the vitamin E- and zinc deficient animals are very susceptible to peroxidative hemolysis (7,10). It was reported that skin and joint abnormalities have been reported in chickens that were fed zinc-deficient diets containing 30 IU vitamin E per kilogram (6).

Skin changes are common in zinc deficiency states in a number of species. In the dog, zinc deficiency may occur for a number of reasons. Diets may have an absolute deficiency of zinc. Relative deficiencies resulting from binding of zinc (phytate and inorganic phosphate) or by competition for intestinal absorption sites from other

dietary (calcium, iron, cadmium and chromium) components appear to be more important (6).

We investigated whether zinc, copper and alpha tocopherol (α -TCP) concentrations have a role in the progress of eczematous lesions in dogs fed only bread, meat or leftover food.

Materials and Methods

Twenty-eight adult dogs with eczema presented to the Clinic of Internal Medicine of in the İstanbul University Veterinary Faculty. They included 6 females and 22 males of varied age (average age 3 years, range 1-5 years). Fourteen dogs were Karabash, seven were German Shepherd and seven were mixed breed (Karabash and German Shepherd). All dogs in the group with eczema (Group-I) were fed unbalanced home diets of bread, meat or leftover food. Twelve dogs were pets, and the others were working dogs. Signs of eczema consisted of Pruritis (mild to moderate), a dull, harsh coat, seborrhoea sicca, bilaterally symmetrical, white/yellow crusts affecting the head, back and limbs, braining or watery lesions and repeat twice every year.

The control group (Group-II) contained 15 age-matched healthy dogs (Karabash), 9 females and 6 males. The healthy dogs fed Hill's Science Diet, Canine maintenance (Hill's Pet Nutrition, Colgate-Palmolive Company, U.S.A.). The healthy dogs were pets belonging to veterinary medicine students and patient owners.

Skin scrapings were taken from lesions. All samples were examined with NaOH (2.5mol/L), microscopically to eliminate the mycosis, scabies or demodicosis. The diagnosis of eczema was made on the basis of skin and laboratory (blood counts, serum alanine aminotransferase, serum aspartat aminotransferase, total protein etc.), as well as history and physical examination findings.

The blood samples were taken from the femoral vein, between 9.30 a.m. and 4.00 p.m.. After clotting, the serum was separated by centrifugation. Serum alanine aminotransferase (ALT), serum aspartat aminotransferase (AST) and total protein levels were studied spectrophometrically at the same day using Ciba-Corning Express Plus Autoanalyser. The erythrocytes, leucocytes, neutrophil, lymphocyte, monocyte and eosinophil counts were detected using an autoanalyser, Medonic CA 570. Serum samples were frozen at -20 0C until assayed for zinc and copper concentrations. The concentrations of Zn and Cu in serum were analysed by the method of Uchida et al. (9). One milliliter serum was added to 5 ml. of Brij 35, (0.3g/L) solution, and then zinc and copper concentrations were determined by atomic absorption spectrophotometer, Thermo Electron 1L 357 A.A.S. (9). Four samples were prepared from each dog to determine α -TCP concentrations as follows: 100 μ L serum samples were pipetted into tubes with an antioxidant, ascorbic acid, dried extracts were then resolved in mobile phase (methanol/water) and detected using an UV detector of a High Performance Liquid Chromatography System (7).

Variance analysis was used for the statistics (2).

Results

The lesions in dogs with eczema were located in different areas of the body (Fig.1). One of them was on the neck, two of them were on the thoracic area, four of them were in the sacral area and twenty-one of them were on the root of tail. Pruritis that was changing mild to moderate were in all animals. The other sings of eczema consisted of a dull, harsh coat, seborrhoea sicca, bilaterally symmetrical, white yellow crusts, scurfy and watery lesions.

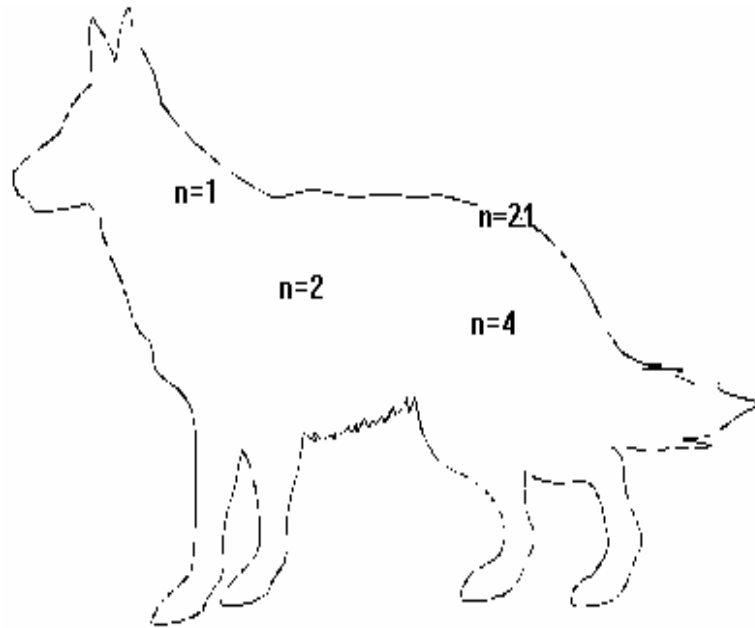


Fig 1: The areas where the lesions were located in dogs with eczema-legend

The erythrocyte count in dogs with eczema was within normal limits. However, leucocyte ($P<0.001$), monocyte ($P<0.001$) counts and, serum AST ($P<0.01$), serum and ALT ($P<0.01$) values were significantly higher within normal limits compared with the control group (Table 1 and 2). The neutrophil, lymphocyte and eosinophil counts were not different from the healthy group (Table 1).

Table 1: Blood count parameters (means±SD).

Group	n	Erythrocyte	Leucocyte	Neutr.	Lymp.	Eosi.	
		(x10⁶/mm³)	(x10³/mm³)	(%)	(%)	(%)	(%)
I	28	6.67±0.77	18.46± 0.77*	70.55±8.78	23.35±10.37	8.64±7.45	
		3.62±1.41*					
II	15	6.57±0.96	10.93±2.81	68.67±7.88	18.67±6.60	8.13±5.61	
		1.73±1.97					

* P<0.001

Table 2: Serum AST, serum ALT and total protein levels (means±SD)

Group	n	AST	ALT	T. Protein
		(U/L)	(U/L)	(mg/dl)
I	28	24.82±21.32*	21.92±19.25*	6.41±1.37
II	15	11.92±7.15	9.92±4.41	6.26±0.54

* P<0.01

Table- 3: Serum zinc, copper and alpha tocopherol concentrations (means±SD)

Group		I (n=28)	II (n=15)
Serum Zinc (µmol/L)	mean	14.53*	9.97*
	SD	5.26	3.87
	range	8.22-21.90	6.64-16.78
Serum Copper (µmol/L)	mean	15.27*	23.77*
	SD	6.73	10.83
	range	7.65-29.15	11.17-30.97
Serum α-TCP (mg/L)	mean	2.5	4.4
	SD	1.9	6.7
	range	0.1-6.8	0.5-7.2

* P<0.05

Serum copper concentrations were significantly lower in dogs with eczema compared to the control group ($P < 0.05$). In contrast to serum zinc concentrations were increased in dogs with eczema ($P < 0.05$). Serum alpha-tocopherol concentrations tended to be lower dogs with eczema compared with the control group, but the difference was not significant ($P < 0.05$) (Table 3).

Discussion

The factor common to previously reported cases all cases has been the feeding of soy- or cereal-based diets with little or no supplementation with canned based food dogs meat or, much less commonly, potentially unbalanced diets from other sources (5,8).

It was reported that plasma and serum zinc concentrations are subject to variations according to stress (3), sex, age and environmental temperature (4), acute and chronic infections and hepatic disease (3). We were unable to find any infection or hepatic disease in our dogs with eczema. However, we found that serum ALT and serum AST levels in the dogs with eczema were higher than in the control group, although both were within normal limits.

Van den Broek (10) reported that the dogs with zinc-responsive dermatitis had significantly lower mean serum zinc concentrations than the normal dogs and those with dermatitis not associated with zinc deficiency, but there was a considerable overlap in the range of concentrations recorded. Therefore, the value of serum zinc concentration in the diagnosis of zinc-responsive dermatitis is limited because a serum zinc concentration below the mean for normal dogs would support but not confirm a diagnosis of zinc deficiency dermatitis. However, a serum zinc concentration greater than the normal mean would be incompatible with such a diagnosis.

Because many dogs owners, feed their pets diets such as bread, meat or leftover food because of that is more cheaper we could see various kind of skin

diseases, especially eczema in dogs. In our study, the dogs with eczema were fed only home unbalanced diets only such as meat, bread or leftover food.

In healthy dogs fed dried or canned commercial food, the percentage of eczema cases was much less. Thoday (8) reported low serum zinc concentrations in five dogs with spontaneously occurring zinc-responsive dermatitis. However, Kunkle (5) did not find consistently low serum zinc concentrations in dogs with zinc-responsive dermatitis. However, in our dogs with eczema, serum zinc levels were higher than those in increased compared to the control dogs.

In this study, copper concentrations significantly lower in dogs with eczema. In contrary to our findings, David et al. (1) reported that atopic eczema in children was associated with a significantly higher serum copper concentration.

In our study, α -TCP concentrations tended to be lower in dogs with eczema compared with the control dogs. However, there was a correlation between copper and α -TCP concentrations ($r=37.5$), suggesting that α -TCP concentrations are associated with the progress of eczema.

These results indicate that the concentrations of copper and zinc in serum, may be indicators in the diagnosis of eczema, together in dogs were fed by unbalanced diet. Although serum α -TCP concentrations may change in dogs with eczema, this parameter has a role only if considered with copper and zinc concentrations.

References

1. David, T.J., Wells, F.E., Sharpe, T.C., Gibbs, A.C. Devlin, J.: Serum levels of trace metals in children with atopic eczema. *British Dermatology*. 1990; 122: 485-489.
2. Evrim, M., Güneş, H.: *Biyometri*. İstanbul. 1994; pp. 27-43
3. Fisher, G.L.: Effect of disease on serum copper and zinc values in the Beagle. *Journal of American Veterinary Research*. 1977; 38: 935-940.
4. Keen, C.L., Lonnerdahl, B., Fisher, G.L. : Seasonal variations and the effects of age on serum copper and zinc values in the dog. *American Veterinary Research*. 1981; 42: 347-351.
5. Kunkle, G.A.: *Current Veterinary Therapy VII: Small Animal Practice*. W.B. Saunders, Philadelphia. 1980; 472-476.
6. Machlin, L.J.: Vitamin E. *Handbook of Vitamins, Nutritional, Biochemical, and Clinical Aspects*, New York, Basel. 1978; pp. 99-198.
7. Nierenberg, D.W., Nann, S.L. : Method for determining concentrations of retinol, tocopherol and five carotenoids in human plasma and tissue samples. *American Journal Clinical Nutrition*. 1982; 56: 417-426.
8. Thoday, K.L.: Diet-related zinc responsive skin disease in dogs: a dying dermatosis. *Small Animal Practice*. 1989; 30: 213-21.
9. Uchida, T., Kojima, I., Lidac, I.: Application of an automatically triggered digital integrator to flame atomic-absorption spectrometry of copper using a discrete nebulization technique. *Analyst*. 1981; 106: 206-212.
10. Van Den Broek, A.H.M.: Diagnostic value of zinc concentrations in serum, leucocytes and hair of dogs with zinc-responsive dermatosis. *Research Veterinary Science*. 1988; 44: 41-44.